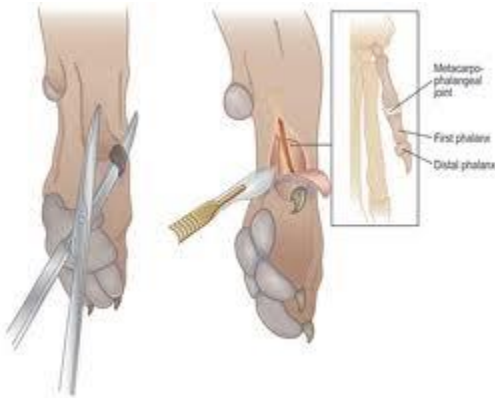


Dewclaws, Running and Arthritis....Is there a link?



Dewclaws are the fifth toe which dogs almost always have on the inside of the front legs and occasionally also on the hind legs. There has been much debate regarding dewclaws. It can be a breeders practice to remove this “extra” toe just after birth. We at Cavachons by Design do not make it our practice to remove dewclaws for the following reasons:

*It actually does hurt the puppies. Anyone who says otherwise has never seen it done. It hurts the puppies during a critical developmental period. Some say the pain of removing a dewclaw is far greater than any future risk of POSSIBLY catching it or ripping it off.

* Some breeders have lost puppies from infections they received at the removed dewclaw area. For this reason, removal of dewclaws is illegal in many countries.

*Dogs need the dewclaws. The dewclaws are not dead appendages. They can be used to lightly grip bones and other items that dogs hold with the paws. (please see further uses for the dew claw in the article below).

* One breed for which lack of dewclaws is considered a fault is the Great Pyrenees. Dewclaws in the Great Pyrenees are attached to the bony structure of the leg. Removal is detrimental to this breed as is in other breeds as well.

The following is an excerpt from “*With A Flick of the Wrist*” by Chris Zink, DVM, PhD (as seen in *Dogs In Canada* – September 2003). It is very enlightening as to what roll removing dew claws can play in injuring dogs and arthritis.

In the last several years, while doing sports-medicine consultations for performance dogs across Canada and the United States, I have seen many canine athletes with carpal arthritis. Interestingly, this condition is much more common in dogs that have had their front dewclaws removed. To understand why, it is helpful to understand the structure of the carpus. This joint consists of seven bones that fit together like fieldstones that are used to build the walls of a house (Figure 2).

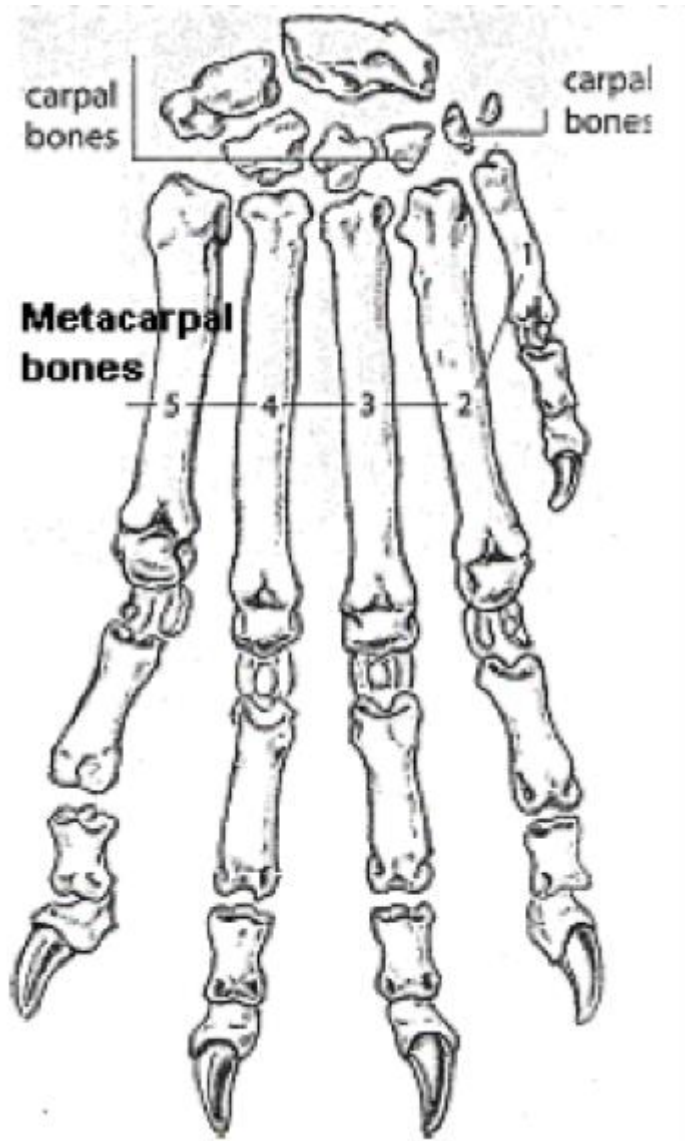


Figure 2: The seven carpal bones fit together like fieldstones in a wall

The carpus joins to the radius and ulnar bones (equivalent to our lower arm) above, and to the metacarpal bones (equivalent to our hand) below.

Each bone of the carpus has a convex or concave side that matches a curve on the adjacent bone. Unlike the bones of the elbow, for example (Figure 3),

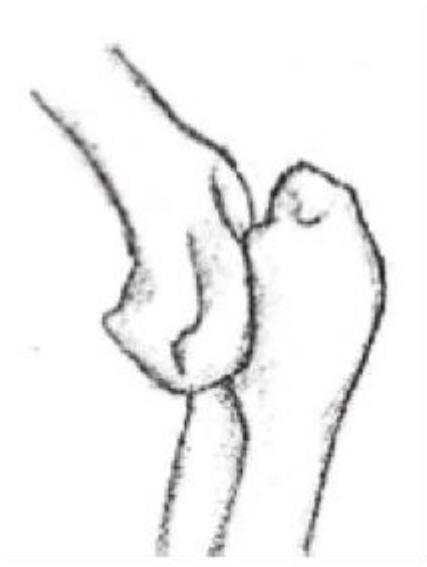

Figure 3: The elbow bones have ridges that slide into interlocking grooves.

the bones of the carpus do not have ridges that slide into interlocking grooves on the adjacent bone. The relatively loose fit of the carpal bones is supported by ligaments that join each of the carpal bones to the adjacent bones. With so many carpal bones that don't tightly interlock with the adjacent bones, the ligaments of this joint can be easily stretched and even torn when torque (twisting) is applied to the leg. The dewclaws have the important function of reducing the torque that is applied to the front legs, especially when dogs are turning at a canter (the main gait used in agility). In the canter, there is a moment during each stride when the dog's accessory carpal pad (on the back of the carpus) of the lead front leg touches the ground (Figure 1) and the rear legs and other




Figure 1: The accessory carpal pad of the lead front leg touches the ground.

front leg swing forward to prepare for the next stride. At this point, the dewclaw is in contact with the ground and if the dog turns, the dewclaw can dig in for extra traction to prevent unnecessary torque on the front leg. Without the gripping action of the dog's 'thumbs' there is more stress on the ligaments of the carpus. This may cause the ligaments to stretch and tear over time, resulting in joint laxity and ultimately, arthritis.

Note: Dewclaw removal is very painful, even to very young puppies, during a critical developmental stage.